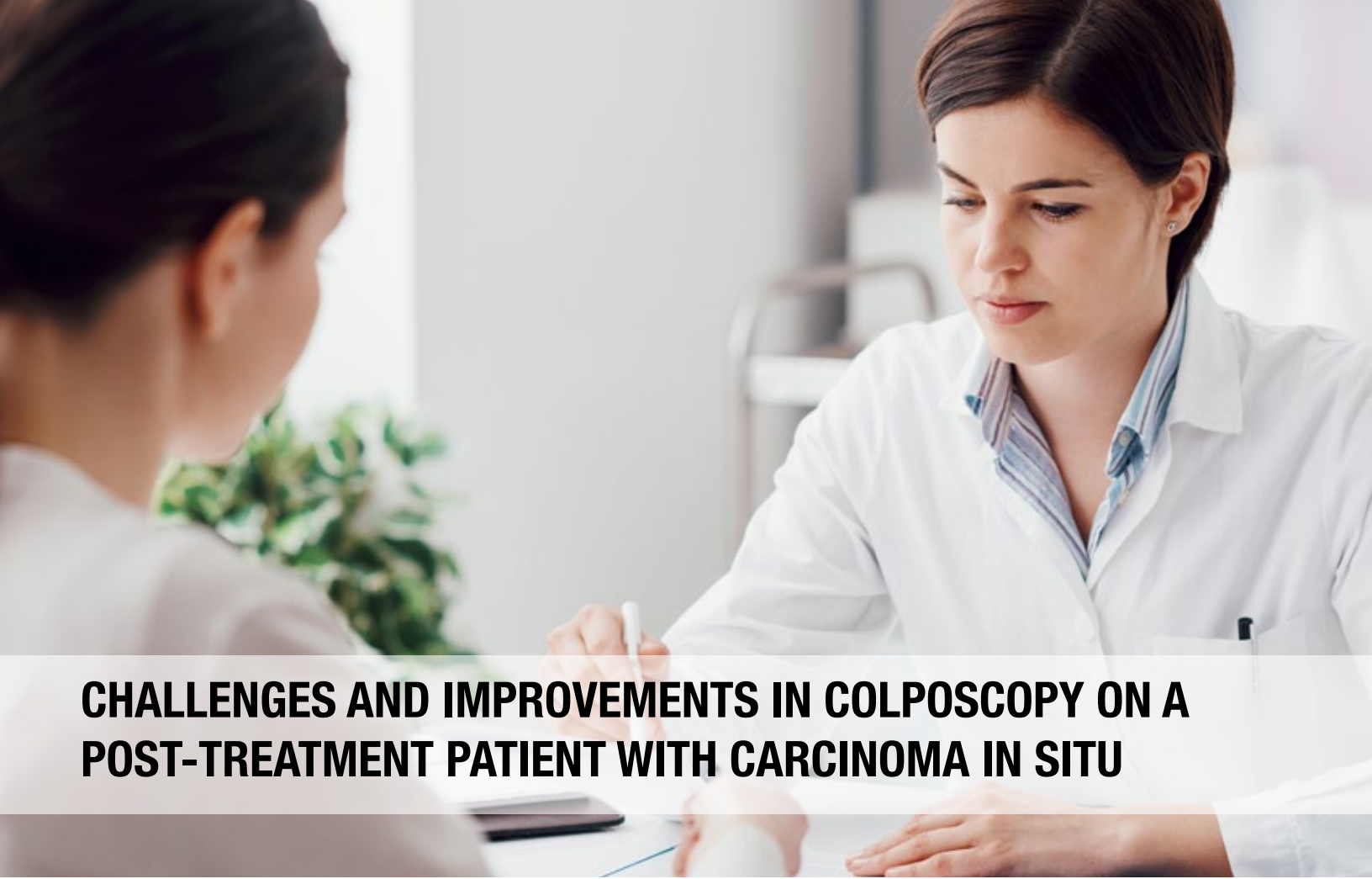


# **CHALLENGES AND IMPROVEMENTS IN COLPOSCOPY ON A POST-TREATMENT PATIENT WITH CARCINOMA IN SITU**

## **A CASE STUDY**

**By Elizabeth Nye, MD**  
Nye Partners in Women's Health  
Chicago, IL



# CHALLENGES AND IMPROVEMENTS IN COLPOSCOPY ON A POST-TREATMENT PATIENT WITH CARCINOMA IN SITU

## A CASE STUDY

by Elizabeth Nye, MD

### BACKGROUND

Women treated for cervical dysplasia are co-tested (cytology/high-risk human papillomavirus) at 12/24 months. Those with a positive result are referred for colposcopy and continue to be monitored as dysplasia progression risk remains elevated.

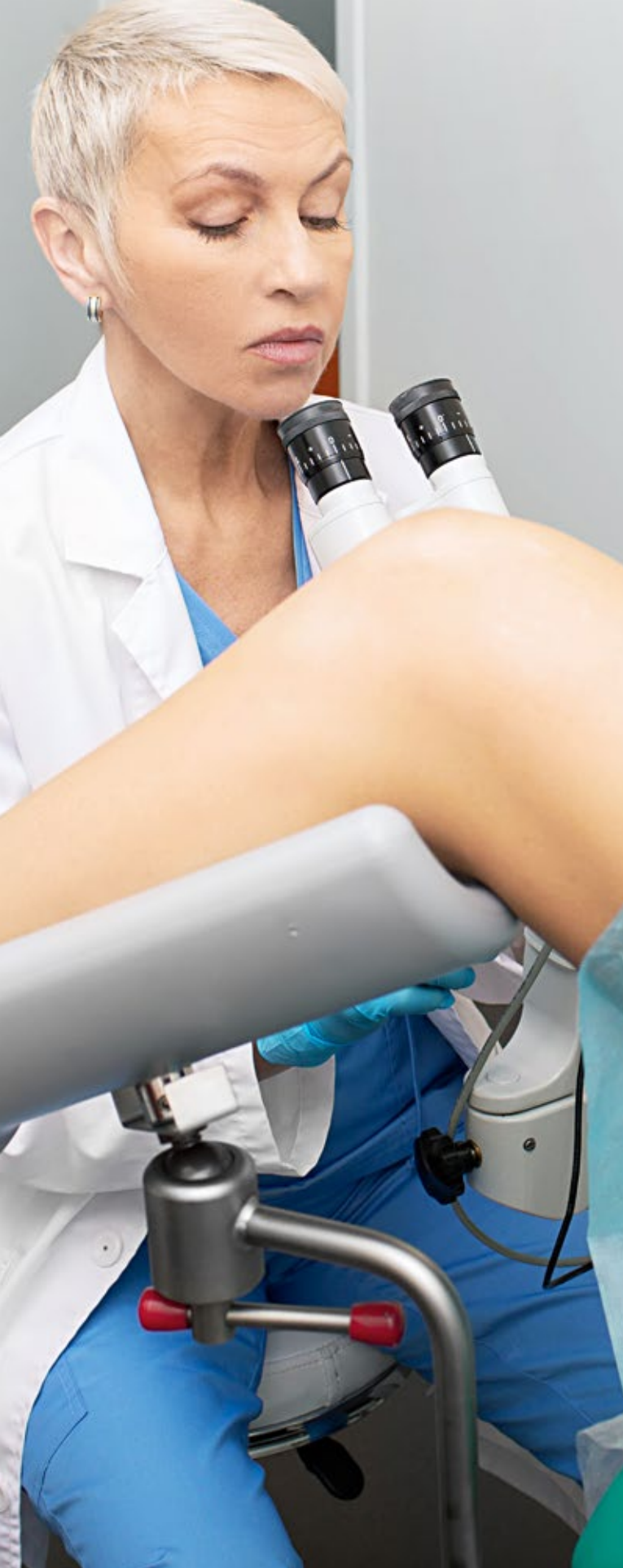### CASE

A 56-year old woman with a history of excisional treatments, abnormal screening tests and persistent low-grade disease had colposcopy following high-grade cytology. She was examined using the DYSIS® Dynamic Spectral Imaging (DSI) map adjunctively

to clinical judgment. Colposcopy was satisfactory and two punch biopsies revealed CIN1; given patient history and age, and corroborated by a large area of positive DSI mapping of the acetowhitening, cold knife conization was performed, which revealed carcinoma in situ in the most intense area of the map.

### CONCLUSION

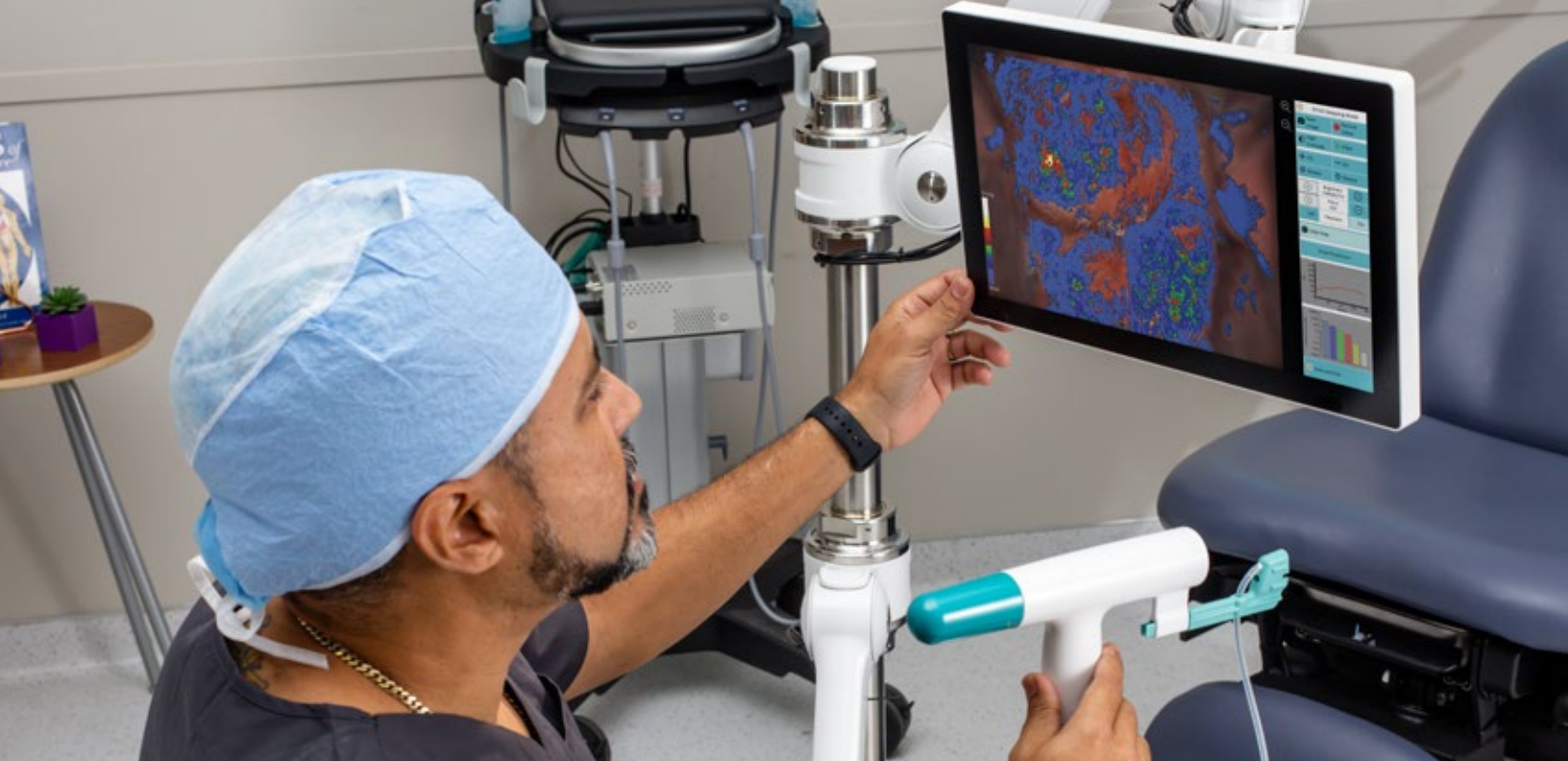Colposcopy on healing epithelium is challenging as cervical morphology differs; in this case, using the DSI mapping adjunctively to colposcopy helped standardize and improve diagnostic and management decisions, reducing risks for the patient.



Colposcopy is an important component of prevention and early treatment of cervical pre-cancer and cancer. It is a subjective examination that suffers from poor performance<sup>1,2,3</sup> and reproducibility<sup>4</sup>, but still plays a critical and challenging role in managing women with a positive screening test. High-grade precancerous lesions are typically excised or ablated<sup>5</sup> and treated patients remain under surveillance. Currently, they have a co-test with cytology and high-risk human papillomavirus (hrHPV) test at 12 and 24 months after being treated; if any of these tests is positive, they are referred to colposcopy<sup>5</sup>.

Treated women represent a fraction of the patients seen at colposcopy overall, and the prevalence of recurrent or residual disease among them is rather low at about 10%. At the same time, the risk for these women to develop recurrent lesions and cervical cancer is higher than that in the general population<sup>6</sup>. The appearance of a healing epithelium is a challenge during colposcopy because it is different to pre-treatment morphology. There is little specific literature on recognizing colposcopy patterns on post-treatment women and how they differ from usual colposcopy, or on the clinical performance of colposcopy to successfully identify cervical intraepithelial neoplasia (CIN) in this group of patients.

Additionally, post-treatment colposcopy is often unsatisfactory, vascularization may resemble that of a malignant lesion without necessarily being one, and epithelial acetowhitening may not be distinct. The need for improvement of colposcopic service to these women is evident.



A new type of digital colposcope (DYSIS, by DYSIS Medical Inc. Atlanta, GA), which integrates a method for mapping the acetowhitening named Dynamic Spectral Imaging (DSI) was recently adopted in our practice. It helps standardize the process of colposcopy and also offers the DSI map, a tool that quantifies cervical acetowhitening and calculates a color-coded map based on its intensity and duration.

The map is tool that is meant be used as an adjunct after a thorough colposcopic evaluation has been completed, and after biopsy site(s) have been selected on the basis of the colposcopic evaluation. The DYSISmap™ may be used to potentially add additional biopsy site(s), but original biopsy selections should never be cancelled because of the DYSISmap. The product has been studied in combination with standard colposcopy and been found to yield additional high grade disease

confirmed by biopsy<sup>7</sup>. The case presented here (after signed consent of the patient) is a colposcopic examination enhanced by incorporating this method, which resulted in the full excision of a cervical carcinoma in situ, potentially preventing the patient from higher risk of progression to invasive cervical cancer and illustrating the benefit of this additional information in clinical decision-making.

### CASE

A 56-year old patient was seen at colposcopy after a High-Grade Squamous Intraepithelial Lesion (HSIL) Pap smear. The patient had a long history of cervical disease, with a first loop electrical excision procedure (LEEP) in 2004, with three normal follow-up cytology results in four years. An abnormal pap, Low-Grade Squamous Intraepithelial Lesion (LSIL), with a positive hrHPV result in 2009 brought her for colposcopy, where no biopsy was taken, but an endocervical curettage

(ECC) was performed, which found evidence of CIN1. At 6 month follow-up, her cytology was LSIL and her hrHPV test positive; an ECC was taken again and the patient was treated by LEEP. The ECC findings were non-dysplastic, and the LEEP specimen was CIN1 with negative margins. An LSIL cytology outcome at 12 months was followed by colposcopy that again found CIN1 in a punch biopsy and ECC. The follow-up cytology was negative, but hrHPV was detected again; the HPV test was negative for genotypes 16/18.

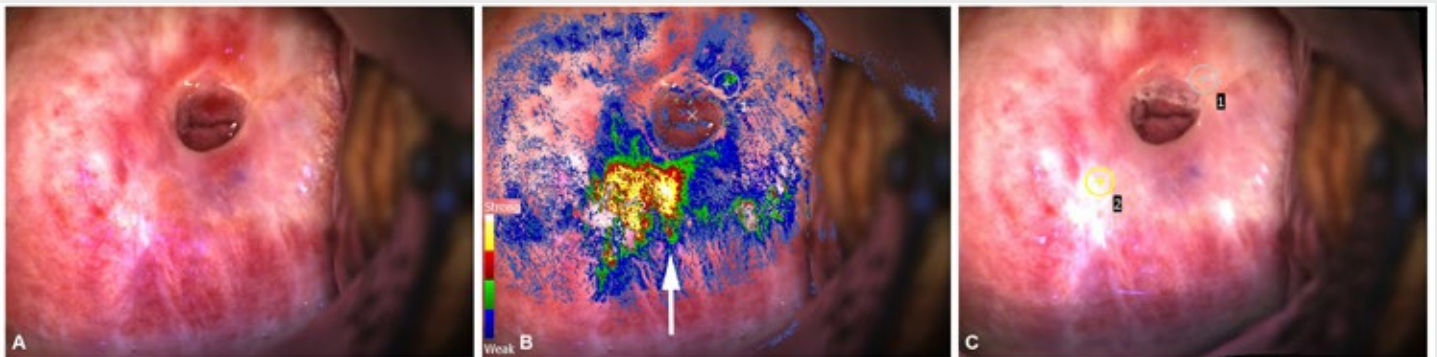
Cytology at 24 months was HSIL and colposcopy plus DSI was performed. The examination was satisfactory but was partially hindered by light reflections on the cervical tissue, which is not unusual on epithelium that has been previously treated. Figure 1A depicts the cervix before acetic acid was applied. Acetic acid was applied and the cervix was observed. The colposcopic

impression was that of a normal cervix prior to seeing the DSI map assessment, with a decision for a single punch biopsy at 1 o'clock. This biopsy site was annotated during the examination, and appears as a gray circular mark, #1, on Figure 1B and 1C. The DSI map analysis was then displayed (Figure 1B) and suggested an area of significant acetowhitening (at 6-7 o'clock). It was then decided to take an additional punch biopsy at 7 o'clock. This biopsy site was also annotated during the examination and appears as a yellow circular mark, #2, on Figure 1B and 1C.

After the punch biopsies were collected, the endocervical canal was also sampled by ECC. Both punch biopsies yielded CIN1 disease, and the ECC was reported as "fragment of unmoored squamous epithelium with dysplasia."

## FIGURE 1

Acetowhitening during colposcopy using the DSI map.



A. Image of the cervix; B. the Dynamic Spectral Imaging map of the acetowhitening and the biopsy annotations overlaid on the image of the cervix. Red, yellow and white areas correspond to intense/lasting acetowhitening. The white arrow indicates the 6 o'clock position where the carcinoma *in situ* was found; C. Biopsy annotations marked by the colposcopist at the time of examination overlaid on the image of the cervix. The gray circular mark (#1) depicts the site selected for biopsy before seeing the map and the yellow mark (#2) depicts the site selected by the colposcopist after reviewing the map.

Given the history of the patient, her age, the positive indication of the HSIL pap and the intense DSI mapping, and despite the low-grade outcome of the two punch biopsies, a new treatment was suggested to and discussed with her, to which she agreed.

Cold knife conization was preferred over LEEP as the patient had already undergone LEEP twice, and conization would allow the margins to be evaluated more reliably. Conization was performed about 5 weeks after colposcopy, and during conization, it was ensured that the excised specimen extended beyond the area that had been depicted as intense acetowhitening in the DSI map.

The pathology lab reported carcinoma in situ (CIS) for the treatment specimen with further clarifications that p16 immunohistochemistry staining was positive, consistent with aggressive HPV types and that the excision margins were free of dysplasia. A suture placed at the 12 o'clock position, marking the orientation of the specimen at time of excision, helped the localization of the CIS finding at approximately 6 o'clock on the ectocervix.

This is actually the area where the DSI map had been the most intense (Figure 1B), suggesting that the second punch biopsy (7 o'clock) was either not taken exactly from the intended site, or that the exact site selected was not the most intense area of acetowhitening on the DSI map, explaining the CIN1 finding of the punch biopsy. The patient has been advised to return at 12 months for follow-up with cytology and hrHPV co-testing.

## COMMENT

Evidence shows that women who have a history of hrHPV infection and have been treated for dysplasia remain at risk for the development of high-grade CIN or invasive cancer (6). This can be either due to recurrence or due to residual disease not fully removed, and the role of follow-up tests is to identify the patients at risk and refer them for colposcopy. Colposcopy on healing epithelium is rather challenging and the case presented in this report illustrates just that. Even though the patient had been through several screening rounds and colposcopic examinations, her significant disease had remain undetected; even though it is uncertain at which point the carcinoma in situ that was eventually found had appeared, it can only be assumed that it developed over a period of years. Persistent disease that remains undetected puts patients at significant risk, not just because of the risk for progression, but also because of the risk that patients may stop complying with follow-up appointments.

For this particular case, the use of the DSI method after standard colposcopy supported us to make the right clinical decision, helped guide the removal of the carcinoma in situ with clear margins and also documented the examination fully in a series of digital images.

**“The need for improvement of colposcopic service to these women is evident .”**

— Elizabeth Nye, MD

## FINANCIAL SUPPORT

Dr. Nye was a Principal Investigator in the IMPROVE-COLPO Study that was sponsored by DYSIS Medical Inc. Otherwise, there is nothing to report.

## REFERENCES

<sup>1</sup>ALTS Group. Results of a randomized trial on the management of cytology interpretations of atypical squamous cells of undetermined significance. *Am J Obstet Gynecol* 2003; 188(6): 1383-92.

<sup>2</sup>ALTS Group. A randomized trial on the management of low-grade squamous intraepithelial lesion cytology interpretations. *Am J Obstet Gynecol* 2003; 188:1393-1400.

<sup>3</sup>Massad LS and Collins YC. Strength of correlations between colposcopic impression and biopsy histology. *Gynecol Oncol* 2003; 89:424-28

<sup>4</sup>Ferris DG and Litaker MS. Interobserver Agreement for Colposcopy Quality Control Using Digitized Colposcopic Images During the ALTS Trial. *J Low Genit Tract Dis* 2005; 9:29-35.

<sup>5</sup>Massad LS, Einstein MH, Huh WK, Katki HA, Kinney WK, Schiffman M, et al. 2012 Updated Consensus Guidelines for the Management of Abnormal Cervical Cancer Screening Tests and Cancer Precursors. *Obstet Gynecol* 2013; 121:829-46

<sup>6</sup>Kreimer AR, Schiffman M, Herrero R, Hildesheim A, González P, Burk R D, et al. Long-term risk of recurrent cervical human papillomavirus infection and precancer and cancer following excisional treatment. *Int J Cancer* 2012; 131:211-8.

<sup>7</sup>Louwers JA, Zaal A, Kocken M, Ter Harmsel WA, Graziosi GCM, Spruijt JWM, et al. Dynamic spectral imaging colposcopy: higher sensitivity for detection of premalignant cervical lesions. *BJOG: An International Journal of Obstetrics & Gynaecology* 2011; 118, 309-18.





## COLPOSCOPY HAS CHANGED.

Ask us how DYSIS® standardizes colposcopy, quantifies acetowhitening and assists clinicians in identifying areas of potential concern to biopsy.

Get in touch     

[info@dysismedical.com](mailto:info@dysismedical.com) | +1 770 847 8482

 **DYSIS**  
Smart Colposcopy

For additional information on use of the DYSIS Colposcopes including applicable regulations, please refer to the DYSIS Digital Colposcope Instructions for Use: 0330-53123.